

## Evaluation of Anterior Cruciate Ligament repair with Iliotibial Band

**Rajat Saran**

Department of Orthopaedics, People's College of Medical Sciences & Research Centre, People's Campus Bhanpur, Bhopal-462037.

### Abstract:

Reconstruction of the anterior cruciate ligament (ACL) is the surgical treatment of choice as direct primary repair of the ligament has been shown to result in persistent laxity and instability of the knee. The aim of reconstruction is to restore stability of the knee without restricting its functions. Anterior cruciate ligament reconstruction requires a graft which may be either an autograft or an allograft or a synthetic graft.

Most studies agree that using the patient's own tissue (autograft) to repair an anterior cruciate ligament tear is the way to go. Graft taken from patellar tendon gives good results but muscle weakness, pain, tendonitis and kneecap fracture are just a few of the possible post-operative problems.

In this prospective study of ACL reconstruction, tendon material from iliotibial tract was used in a special way for adding stability to the knee called *iliotibial band tenodesis*. Herein, 17 cases of ACL repair and augmentation with iliotibial tract is being evaluated.

**Key Words:** Anterior cruciate ligament, iliotibial band, tenodesis.

---

### Introduction:

Reconstructions of the anterior cruciate ligament (ACL) are among the most frequently performed procedures in knee surgery nowadays. In the past ACL was a structure that was never touched by a scalpel. However, since the early 20th century, there has been increasing awareness of, and interest in, the ligament and its lesions and repair.

As far back as 1845, Bonnet wrote a treatise on joint disorders causing haemorrhagic effusion, in which he analyzed knee injuries. He described three essential signs indicative of acute ACL rupture: a snapping noise, haemarthrosis and loss of function "in patients who have not suffered a fracture".

In 1895, Mayo performed the first cruciate (as it was then called crucial) ligament repair in a 41-year-old miner who was injured 36 months back. The case was not reported in the literature until 1903. In 1917, Groves performed the first ACL reconstruction using an iliotibial band transplant.

In 1935, Campbell for the first time used a tibia-based graft of the medial one-third of the patellar tendon, the prepatellar retinaculum, and a portion of the quadriceps tendon. In 1939, Macey described the first technique using the semitendinosus tendon.

In 1979, Marshall et al harvested the central one-third of the entire extensor group of muscles with

a wider portion taken from the prepatellar aponeurotic tissue which was tubed to give greater strength to what would otherwise have been a relatively thin area of the graft. The graft was routed "over the top" of the lateral femoral condyle, and attached with sutures or a staple. The final portion was taken back to be attached to Gerdy's tubercle. In 1975, Rubin et al developed an experimental model of a prosthetic ACL made up of Dacron. In 1981, Dandy was the first to implant a carbon fibre-reinforced ligament substitute, using an arthroscopic procedure. The results were poor.

As carbon fibre went out, Dacron and Gore-Tex came in, and the "arthroscopy generation" of surgeons seized on these synthetic materials as a means of performing ACL reconstructions quickly with minimal trauma. At the same time, metal interference screws were introduced into orthopaedic surgery.

In 1982, Lipscomb et al started using pes anserinus (semitendinosus & gracilis) tendons pedicled on the tibia for ACL reconstruction. In 1988, Friedman pioneered the use of an arthroscopically assisted four-stranded hamstring autograft technique. Pinczewski et al (1997) used an "all-inside" technique with special large (8 mm) round-headed interference screw known as the RCI screw. Other leading surgeons started using hamstring tendons with different means of fixation. Rosenberg (1993) devised fixation with the so-called "Endo-Button" that locked itself against the lateral aspect of the femoral condyle. Paulos et al (1991) used a polyethylene anchor; Staehelin & Weiler (1997) tried biodegradable interference screws.

---

**Corresponding Author:** Dr. Rajat Saran, E-7, 468 Arera Colony, Bhopal-462016

**Phone No.:** 0755-2420820, 9826052044

**E-mail :** saran.rajat@gmail.com

**Material & Methods:**

From January 1995 to July 2010, 23 patients of classical acute midsubstance tear of anterior cruciate ligament were diagnosed by clinical, radiological (skiagrams & MRI-Fig.I) and arthroscopic evaluation. Out of these 23 cases, 6 cases were lost to followup post-operatively within the first year. The maximum follow up in these lost six cases was for a period of 8-10 months, hence they were excluded from the study.

Out of the seventeen cases included in this study, 12 were males and 5 were females. The age

running and walking on uneven ground. Swelling of the affected knee and synovitis was present in all the cases. Thirteen patients had a full range of extension while only seven could flex the knee completely. Six patients had a positive anterior drawer test and four demonstrated a positive Lachmann test.

**Inclusion criteria:** Midsubstance tear of ACL with or without associated: lateral or medial meniscus injuries, lateral ligament injuries and absence of lateral instability.

**Exclusion criteria:** Comprised of proximal and terminal avulsions of ACL from the femur and tibia and lateral instability.

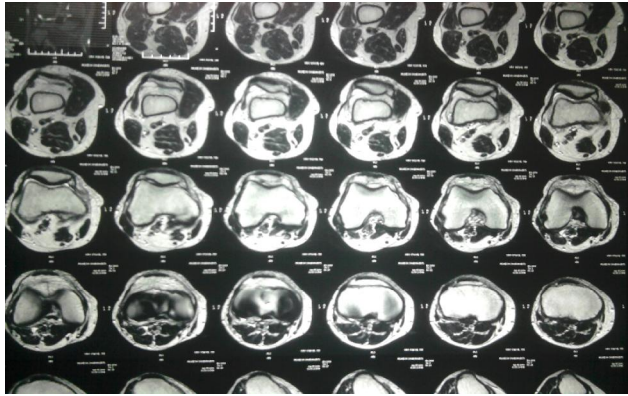


Fig. I: Showing MRI of ACL tear

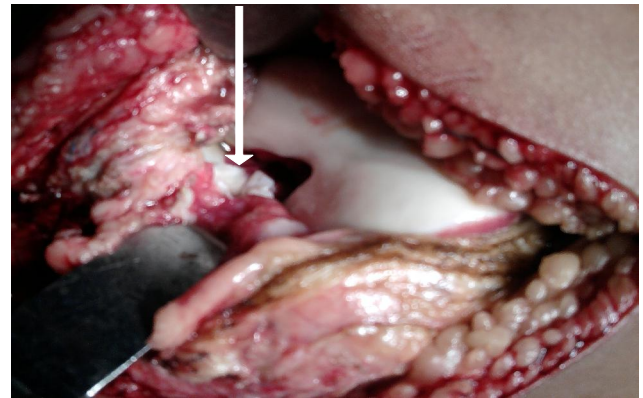


Fig. III: The arrow showing torn ACL.

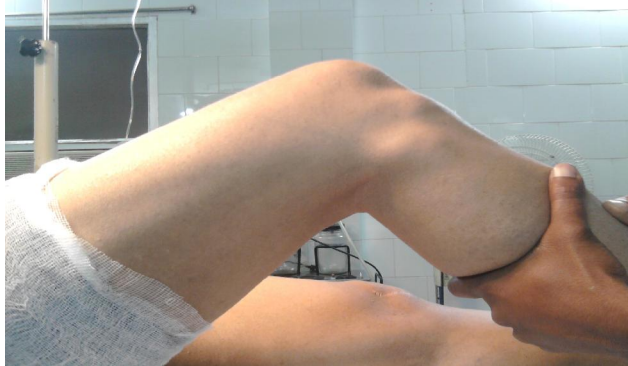

Fig. II: Showing anterior tibial translation.

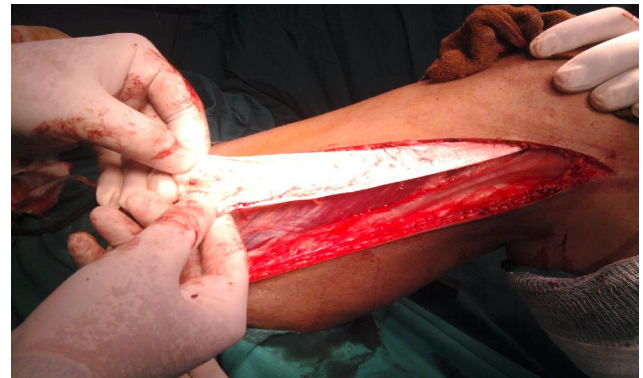

Fig. IV: The strip of iliotibial band.

ranged from 24 yrs to 46 yrs. with an average age of 32 yrs. The mode of injury in these patients varied: nine patients sustained knee injury due to road traffic accidents mostly with motorcycles; four patients gave a history of fall while walking or running with a significant twist of the injured knee and two patients sustained injury while playing football, on the field . A lady missed a step on the stairs and fell and another patient skidded off a motorbike. Three patients distinctly heard an audible pop at the time of injury.

The history and clinical examination suggested that most of the patients had a feeling of the knee giving way, instability and an apprehension of a fall while

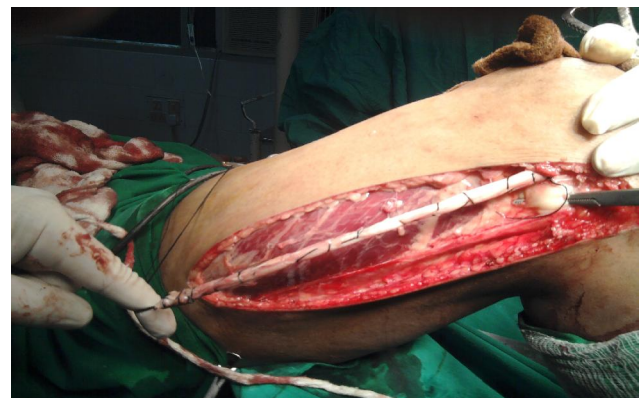


Fig. V: Showing the illotital tract strip rolled into a tube.

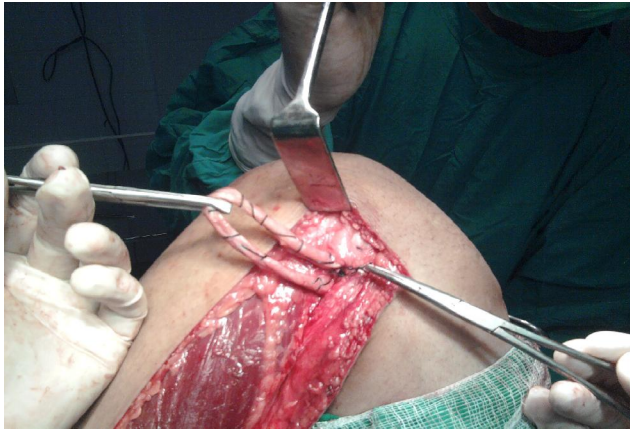

Fig. VI: Showing the strip passed underneath the fibular collateral ligament.

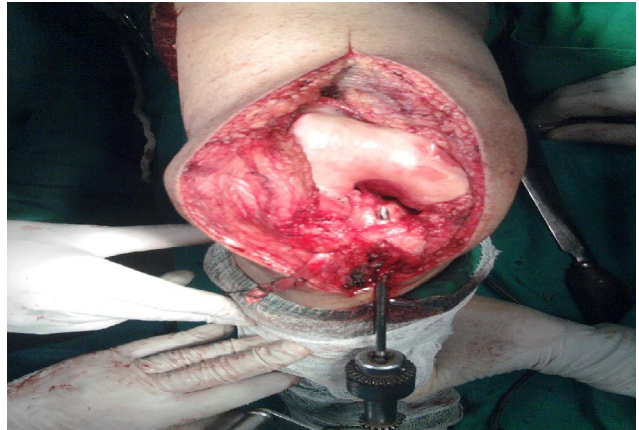


Fig. VIII: The hole being drilled into the medial aspect of tibia for the iliotibial band.

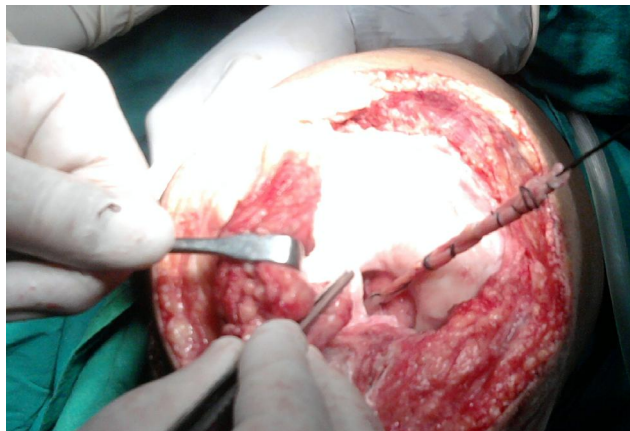


Fig. VII: The strip brought into the joint from 'over the top' of the lateral femoral condyle and through the upper most posterior part of capsule.

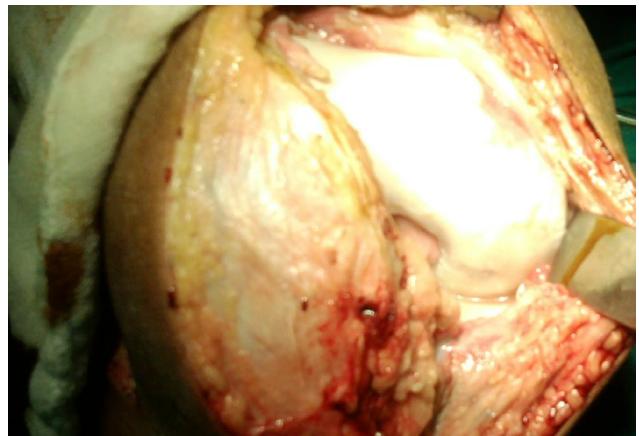


Fig. IX: The arrow showing reconstructed ACL in position.

Skiagrams were taken routinely to exclude associated fractures. Seven patients had an exclusive tear of the anterior cruciate ligament. In rest of the cases concomitant injuries like lateral meniscus, medial meniscus and medial collateral ligament were encountered. The average time period between the injury and surgery was six weeks.

The operative technique adopted in this series was as described by Marshall et al (1979) with minor modifications to cater to the needs of the patient.

A paramedian incision of the knee was used in the earlier cases but later as a modification a midline incision was preferred with the knee flexed to ninety degrees. This relaxes the tension on the incision when the knee is extended from this position. After correcting all intra-articular pathologies, sutures were placed in the anterior cruciate ligament stumps and carefully secured for later use.

A strip measuring approximately 3.5 to 4 cms. wide and 15 to 20 cms. long of the Iliotibial band

(iliotibial tract) was freed from the anterior two third of the iliotibial band and was left attached to its distal attachment to the tibia specially Gerdy's tubercle (Fig.IV). The posterior third portion of the iliotibial band running from the tibia to the femoral epicondyle was preserved as it acts as an effective static tibiofemoral ligament and its detachment may result in a potentially severe varus and internal rotation instabilities. The remaining band was approximated longitudinally.

The strip was rolled into a tube with unabsorbable running sutures with knots at intervals (Fig.V) and was passed beneath the fibular collateral ligament as close to its femoral attachment as possible to prevent its becoming slack later on (Fig.VI), and sutured to the osteoperiosteum with the knee flexed to ninety degrees and the foot in external rotation.

The "over the top" point was selected at the flare of the femoral condyle & a slot was roughened out for the placement of the strip. A hole was then prepared in the uppermost part of the posterior capsule of the knee joint for the passage of the strip into it (Fig.VII - this position prevents slipping of the strip

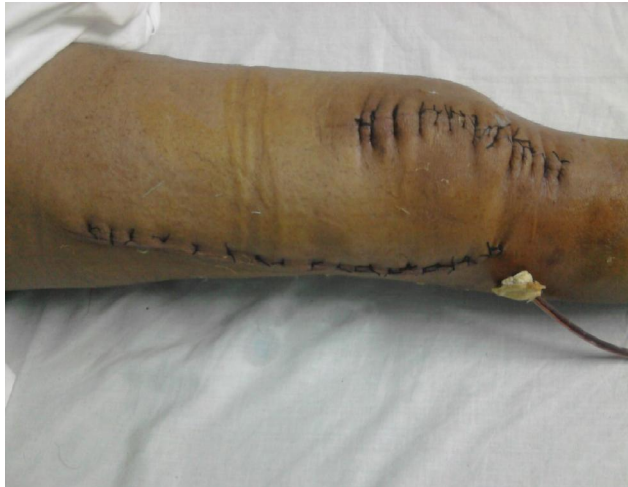

Fig. X: Showing the centrally placed (modified) anterior and the conventional lateral incisions.

from the femoral condyle). It was then pulled into the anterior part of the knee joint tightly over the top in the slot prepared, deep to the lateral intermuscular septum attached on the femoral condyle and placed medial to the repaired ligament. Then it was passed through a tunnel created in the tibia from the anterior intercondylar eminence to a point 4 cms below the joint line on the medial aspect of the tibia medial to the tibial tuberosity (Fig. VIII). The terminal end of the strip was sutured with nonabsorbable sutures to the soft tissues and to an osteoperiosteal flap. The sutures of the stumps of the torn ACL were now tied and the iliotibial band strip was attached to the repaired ligament. A vascular fat pad graft was attached to the repaired ligament with two or three absorbable sutures.

This technique combines the advantages of both the intra and extra-articular features. The part running from the Gerdy's tubercle beneath the fibular collateral ligament and "over the top", if properly placed, not only is isometric with the intra-articular anterior cruciate ligament but is an effective internal rotation checkrein. The extra-articular component helps protect the intra-articular repair and augmentation during the revascularization and recollagenization.

After treatment included an emphasis on accelerated rehabilitation with active movements of the knee from the second post-operative day onwards. No form of immobilization (plaster, brace etc.) was instituted. The goals of the first two weeks were: to eliminate swelling due to activity; progress from partial weight bearing to full weight bearing exercises; regain normal range of motion and to increase the strength of quadriceps and hamstring.

Initial physical therapy consisted of range of motion (ROM) exercises: continuous passive motion (CPM) devices and isometric exercises. Knee extension within two weeks is important. Approximately six weeks is required for the graft to attach to the bone. However, the patient can walk on their own and perform simple physical tasks prior to this with caution, relying on the surgical fixation of the graft until true healing (graft attachment to bone) has taken place. After twelve weeks of surgery, the patient can begin a more aggressive regimen of exercises involving stress on the knee with increasing resistance.

### Result:

Results were measured by asking following questions to the patient:

- Ability to return to a preinjury level of activity and range of movements.
- Pain or instability during walking, standing or running
- Satisfaction with the operation
- Willingness to have the same operation again

The longest follow up recorded in the present series is of fifteen years with an average of 7.79 years.

Almost all the seventeen patients could return to the preinjury level of activity, feeling confident during walking and standing without an anterior translation of tibia during weight bearing. A hopping test was carried out at the end of 12 weeks; none of the patient had any problem going through it.

All patients were painless after a sincere stretch of a rehabilitation program carried out for a minimum period of six months starting from the second post-operative day. Nobody complained of anterior knee pain or a fracture of the patella. Two patients complained of scar hypertrophy (keloid) and one complained of pain at the site of tenodesis for the first 6-8 months which gradually subsided. One patient also had a minor harmless herniation of the quadriceps muscle on the lateral aspect of the thigh.

There was no complaint of the knee giving way or anterior translation of the tibia while walking. In two patients the operated knee was slightly lax as compared to the normal one but was asymptomatic. Anterior drawer test and Pivot shift test were negative in all the cases. The final outcome was evaluated on the basis of Tegner's activity scale:

Levels	Interpretation
1. Levels 7-10	Competition Sports
2. Levels 4-6	Physical fitness activities and moderate to strenuous work activities
3. Levels 1-3	Light work and activities of daily living
4. Level 0	Permanent Disability

One patient attained the highest level, returning back to his profession of a physical instructor and a football coach. Fourteen patients attained the second level while two patients reached the third level.

**Discussion:**

Looking at the history of ACL surgery, it is amazing to see how long it took for some diagnostic and management techniques to establish themselves. Long ago, the ACL was a structure that was never operated upon. However, since the early 20th century there has been increasing awareness and interest in the ligament and its lesions.

In 1981 Dandy was the first to implant a carbon fibre-reinforced ligament substitute using an arthroscopic procedure. The results were poor. Unfortunately, carbon deposits were found in the synovial membrane and the liver, which put a stop to the further use of this technique.

Carbon fibre were replaced by synthetic materials like Dacron and Gore-Tex by surgeons for arthroscopic ACL reconstruction with minimal trauma. However, towards the end of the 80s, there was an unacceptably high rate of synovitis and subsequent rupture of the neoligaments.

No ideal graft site for ACL reconstruction exists, they all have advantages and disadvantages. Jone’s procedure (1963) involving the free bone-tendon-bone graft of the central one-third of the patellar tendon was once considered to be a “gold standard” for knee stability by surgeons. However, it suffered a slightly higher complication rate. The disadvantages included: increased wound pain, increased scar formation as compared to a hamstring tendon operation, risk of fracturing the patella during harvesting of the graft, increased risk of tendinitis and increased level of pain with activities that require kneeling. This was the time when metal interference screws were introduced in orthopaedic surgery.

In 1987, Kurosaka et al showed that the mechanically weak link of the reconstructed graft was its fixation. The research had clearly showed that 9-mm diameter cancellous screws were much superior to other fixation systems. Within a few years such

screws came to be made of resorbable materials such as Polylactic acid (1992) or Polyglycolic acid (1990).

In 1982, Lipscomb et al started using pes anserinus (semitendinosus and gracilis) tendons pedicled on the tibia, for ACL reconstruction.

Unlike the patellar tendon, the hamstring tendon’s fixation to the bone can be affected by motion in the post-operative phase. Therefore, following surgery, a brace is often used to immobilize the knee for one to two weeks during which the most critical healing takes place. Evidence suggests that the hamstring tendon graft does just as well, or nearly as well, as the patellar tendon graft in the long-run .

The procedure of Marshall et al (1979) adopted for the present study provides the combined benefits of the intra-articular as well as the extra-articular fixation. Extra-articular reconstruction uses the structures on the lateral side of the knee to mimic the actions of ACL. By surgically tightening the iliotibial tract, excessive lateral excursion of the tibia is prevented. Intra-articularly it involves a tibially based graft, which means that the strongest part of the graft occupies the tibial tunnel. The overall aim is to prevent anterior subluxation of the lateral tibial plateau in relation to the lateral femoral condyle and to correct anterolateral rotatory instability. Load sharing between the intra and extra articular elements may also occur. A graft from the iliotibial tract has satisfactory mechanical properties and results in less anterior knee pain. However, there is a long lateral operative scar, with a minimal risk of herniation of the quadriceps muscle laterally.

The future holds every prospect of further progress being made. As suggested by Imbert (1994), it is likely that ligament replacements will take the form of “bioimplants” produced with the aid of cell and tissue culture techniques. Perhaps, fresh lesions will be made to heal with gene therapy. The last word has not yet been said in the fascinating story of ACL surgery.

**Bibliography:**

1. Bonnet A: Traité des maladies des articulations (vol. 1 & 2) J.B. Baillière, Librairie, Paris, 1845.
2. Campbell W C: Repair of the ligaments of the knee: Report of a new operation for the repair of the anterior cruciate ligament. *Surgery Gynecology & Obstetrics*, 1936; 62: 964-968.
3. Dandy DJ: Arthroscopic surgery of the knee. Churchill Livingstone, Edinburgh, 1981.
4. Friedman M U: Arthroscopic semitendinosus (gracilis)

- reconstruction for anterior cruciate ligament deficiency. *Techniques in Orthopaedics*, 1988;2(4):74-80.
5. Groves H E W: Operation for the repair of cruciate ligament. *Lancet*, 1917;190(4914):674-676.
  6. Howell S M: Arthroscopically assisted technique for preventing roof impingement of anterior cruciate ligament grft illustrated by the use of an atogenous double-looped semitendinosus and gracilis graft. *Operative techniques in Sports Medecine*, 1993;1(1):58-65.
  7. Imbert JC: Développement technique des ligamentoplasties intra-articulaires. *Réunion annuelle de la Société Française d'arthroscopie*, 1994;15-16.
  8. Johnson L L: The outcome of a free autogenous semitendinosus tendon graft in human anterior cruciate ligament reconstructive surgery: A histological study. *Arthroscopy*, 1993; 9(2): 131-142.
  9. Jones KG: Reconstruction of the anterior cruciate ligament. A technique using the central one-third of the patellar ligament. *The Journal of Bone & Joint Surgery*, 1963;45A:925-932.
  10. Kurosaka M, Yoshiya S, Andrish J T: A biomechanical comparison of different surgical techniques of graft fixation in anterior cruciate ligament reconstruction. *American Journal of Sprots Medicine*, 1987;15(3):225-229.
  11. Lipscomb A B, Jonhston R K, Synder R B: Warburton M J, Gilbert PP: Evaluation of hamstring strength following use of semitendinosus and gracills tendons to reconstruct anterior cruciate ligament. *The American Journal of Sports Madicine*, 1982;10(6):340-342.
  12. Macey H B: A new o perative procedure for repair of ruptured cruciate ligament of the knee joint. *Surgery Gynecology & Obstetrics*, 1939;69:108-109.
  13. Marshall J.L., Warren R.F., Wickiewicz T.L, Reider B: The anterior cruiciate ligament a technique of repair and reconstruction. *Clinical Orthopaedics and related research*, 1979;143:97-106.
  14. Marshall J L, Warren R F, Wickiewicz T L: Primary Surgical Treatment of anterior cruiciate ligament lesions, *The American Journal of Sports Medicine*, 1982;10(2):103-107
  15. Mayo R A W: Ruptured cruciate ligaments and their repair by operation. *Annal of Surgery*, 1903; 37: 716-718.
  16. McIntosh DL, Teganning RJA: A follow up study and evaluation of "over the top" repair of acute tears of anterior cruciate ligament. *Clinical Orthopedics & Related Research*, 1975;113:212-236.
  17. Paulos L E, Cherf J, Rosenberg T D: Anterior cruciate ligament reconstruction with autograft. *Clinical Sports Medicine*, 1991;10:469-485.
  18. Pinczewski LA , Clingeffer A J, Otto D D, Bonar S F, Corry I S: Integration of hamstring tendon graft with bone in reconstruction of the anterior cruciate ligament. *Arthroscopy*, 1997; 13(5):641-643.
  19. Pinczewski L A, Thuresson P, Otto D D, Nyquist F: Arthroscopic posterior cruciate ligament reconstruction using four-strand hamstring tendon graft and interference screws. *Arthroscopy*, 1997;13 (5) : 661-665.
  20. Rosenberg T D: Technique for endoscopic rmethod of ACL reconstruction. Technical Bulletin. Mansfield. MA. Acufex Microsurgical. 1993.
  21. Rubin R M, Marshall J L, Wang J: Prevention of knee instability : experimental model for prosthetic anterior cruciate ligament. *Clinical Orthopedics and related research*, 1975;113: 212-236
  22. Stahelin A C, Weiler A: All-inside anterior cruiciate ligament reconstruction using semitendinosus tendon and soft threaded biodegradeble interference screw fixation. *Arthroscopy*, 1997;13(6):773-779.
  23. Tegner Y, Lysholm J: Rating system in the evaluation of kind ligament injuries. *Clinical Orthopedics & Related Research*, 1985;(9):43-49.