

A Clinical and Optical Coherence Tomography Study of Coloboma in a Tertiary Health Care Centre of Uttar Pradesh

Naveen Sirohi, Jitendra Kumar, *Prayas Vats

Department of Ophthalmology, Maharani Laxmi Bai Medical College, Jhansi, Uttar Pradesh, India, *Consultant, Radiodiagnosis, Fortis Hospital, Delhi

ABSTRACT

This prospective research aimed to study the clinico-etiological features of patients with coloboma, consisted of 124 eyes of 80 patients with coloboma. Demographic and clinical data included age at presentation, gender and parental consanguinity. The best-corrected visual acuity was measured with a Snellen chart or Teller chart where possible. The presence of associated ocular anomalies and history of prophylactic laser photocoagulation was recorded. Standard Domain Optical Coherence Tomography (SDOCT) was done in cooperative patients. Mean age was 11.8 ± 2.25 years (1 month to 25 years). Parental consanguinity was documented in 7(8.75%) of the patients. 44 (55%) patients had bilateral colobomata and 36 (45%) had unilateral involvement. Among 80 patients, 25 (31.25%) cases had anterior colobomas, 31 (38.75%) cases had posterior involvement and 24(30%) cases had both anterior and posterior colobomas. Concurrent ocular anomalies were microphthalmia (32 cases, 40%), amblyopia (24 cases, 30%), strabismus (12 cases, 15%), cataract (10 cases, 12.5%), microcornea (9 cases, 11.25%), and nystagmus (13 cases, 16.25%). OCT in 11 cases showed a “Y-shaped” retina with a fusion of retinal layers and abrupt transition zone between the normal retina into the intercalary membrane (ICM) at the level of the coloboma was seen in 9 cases. Coloboma accounts for 3-11% of blindness in children worldwide. Early onset visual loss have profound consequences on a child's socio-psychological development. Timely diagnosis of coloboma, needful information to the parents regarding the disorder/ anomaly and visual rehabilitation of such subjects should be a priority. Genetic counselling may provide a pivotal role.

KEY WORDS: coloboma, congenital ocular anomalies, optical coherence tomography (OCT)

INTRODUCTION:

The term coloboma is derived from the Greek word koloboma (meaning “mutilated” or “curtailed”). Colobomas are congenital ocular defects (hole in structures of eye) that can affect the iris, the lens, the choroid, the retina, and the optic nerve.^[1] Coloboma is defined as a congenital defect in uveal tissue in a site consistent with abnormal closure of the embryonic fissure. Microphthalmos with cyst is a distinct phenotypic form of coloboma.^[2] The number of cases is around 0.5 to 0.7 per 10,000 births, making it a relatively rare condition.^[3]

The underlying aetiology of the phenotype is the failure of the ectodermal optic vesicle fissure to

close.^[4] This leads to colobomata affecting one or more areas of the eye including the cornea, iris, ciliary body, lens, retina, choroid, and optic nerve. Eyelid coloboma has also been described, but this is thought to arise from failure of the mesodermal folds to fuse at about 7–8 weeks of gestation. The typical, most commonly observed, ocular coloboma is seen in the inferonasal quadrant.^[5] Colobomata in other quadrants are atypical and the embryologic basis for these is unclear. Because the optic fissure forms at the bottom of the eyeball during development, colobomas occur in the lower half of the eye. The particular structure within the eye affected by the coloboma depends on the part of the optic fissure that failed to close.^[6]

Ocular colobomata are frequently seen in association with other developmental defects. In the eye, coloboma is often associated with microphthalmos and anophthalmia.^[7] Microphthalmos with cyst in one eye may be associated with a coloboma in the fellow eye, and both phenotypes may be seen in different individuals of the same family.^[8] People with coloboma may also have cataract,

Corresponding Author:

Dr Jitendra Kumar,
Associate Professor,
Head of the Department,
Department of Ophthalmology,
Maharani Laxmi Bai Medical College,
Jhansi, Uttar Pradesh, India
Phone No.: 9794499137
E-mail: nit.nav@rediffmail.com



glaucoma, myopia, nystagmus), or retinal detachment.^[9] Systemically, a large number of congenital defects are associated with coloboma, including craniofacial anomalies such as cleft lip, skeletal defects such as thumb hypoplasia, and genitourinary anomalies such as horseshoe kidney. Colobomas are seen in Treacher Collins syndrome, in association with cryptophthalmos (absence of eyelid formation), Cat eye syndrome (chromosome 22 abnormality with vertical iris colobomas), Patau syndrome (trisomy 13), Fraser syndrome, Manitoba Oculotrichoanal syndrome, Goldenhar syndrome, First arch syndrome, Franceschetti syndrome, Amniotic band syndrome, CHARGE syndrome (composed of coloboma, heart defects, choanal atresia, growth retardation, genital abnormalities and ear abnormalities), renal coloboma syndrome, Aicardi syndrome, Solomon syndrome, and Noonan syndrome.^[10]

The grading of the coloboma was done according to the Ida Mann classification^[11] as per following details: Type 1: coloboma extending above the anatomic disc; Type 2: coloboma extending up to superior border of disc (Figure 2); Type 3: coloboma extending below the lower border of disc; Type 4: coloboma involving the disc only; Type 5: coloboma present below the disc with normal retina above and below the coloboma (Figure 1); Type 6: pigmentation present in the periphery; Type 7: coloboma involving only the periphery. Media opacities precluding accurate grading were graded as zero for this study.

A complete iris coloboma involves the pigment epithelium and stroma giving rise to the so-called “keyhole” pupil, which can be unilateral or bilateral.^[12] A partial coloboma involves only the pupillary margin making the pupil oval. Occasionally, the coloboma only affects the iris pigment epithelium and can be seen only on trans-illumination.^[13] Chorioretinal coloboma affecting the posterior segment of the eye can be unilateral or bilateral. If the fetal fissure fails to close posteriorly, then a coloboma affecting the retinal pigment epithelium (RPE), neurosensory retina, or choroid may occur. The defect is a bare sclera with the overlying RPE, retina, or choroid missing. In some cases although the retina is present, it is hypoplastic and gliotic.^[12] Typically occurring in the infero-nasal quadrant, it may extend to include the optic nerve. Macular coloboma, which is not due to defects in optic fissure closure, should not be confused with chorioretinal coloboma. The severity varies from no involvement to an obviously enlarged optic cup to gross anomaly unrecognizable as an optic nerve head.^[14]

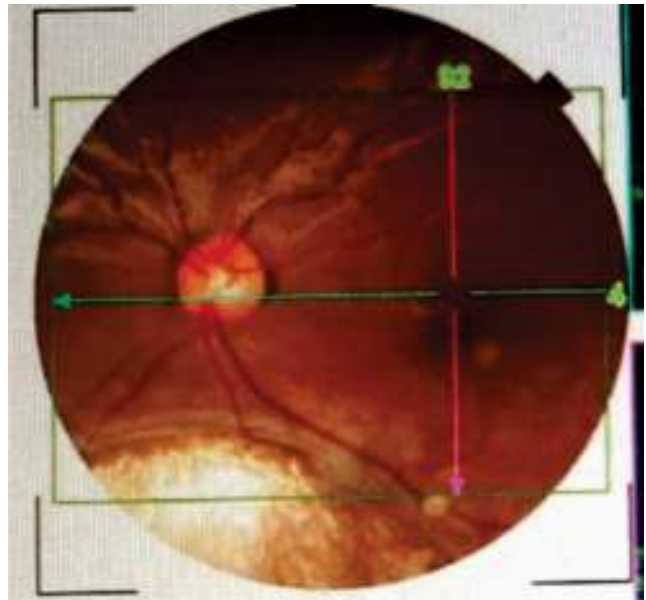


Figure 1: fundus photograph of left eye of a 6 years old male patient showing coloboma present below the disc with normal retina and optic disc above.

Coloboma may occur by genetic, environmental (teratogens),^[15] or unknown factors. Autosomal dominant (AD) inheritance is the most common mechanism reported, although most cases are sporadic.^[16] Consanguineous pedigrees do support autosomal recessive inheritance for both colobomatous microphthalmos^[17] and microphthalmos with cyst.^[18] An unusual molecular mechanism, such as trinucleotide expansion, has been suggested for one pedigree with isolated coloboma.^[19] Studies suggest that the use of various drugs during pregnancy may be associated with ocular coloboma. Children of expectant mothers treated with thalidomide manifested a number of eye malformations including coloboma (4%) and microphthalmos (7%).^[20] Eye abnormalities have been shown to occur in over 90% of children with fetal alcohol syndrome (proportion having coloboma).^[21]

Optical coherence tomography (OCT) studies show that the margin of the coloboma either gradual transitions or sudden change into an intercalary membrane (ICM).^[22] This ICM can include inner retina, glial tissue, and thin connective tissue.^[23] (Figure: 3).

MATERIALS AND METHODS:

A total of 124 eyes of 80 patients having coloboma (inclusive of 44 patients with bilateral findings attending) the Outdoor Patient Department of Maharani Laxmi Bai Medical College, Jhansi, Uttar

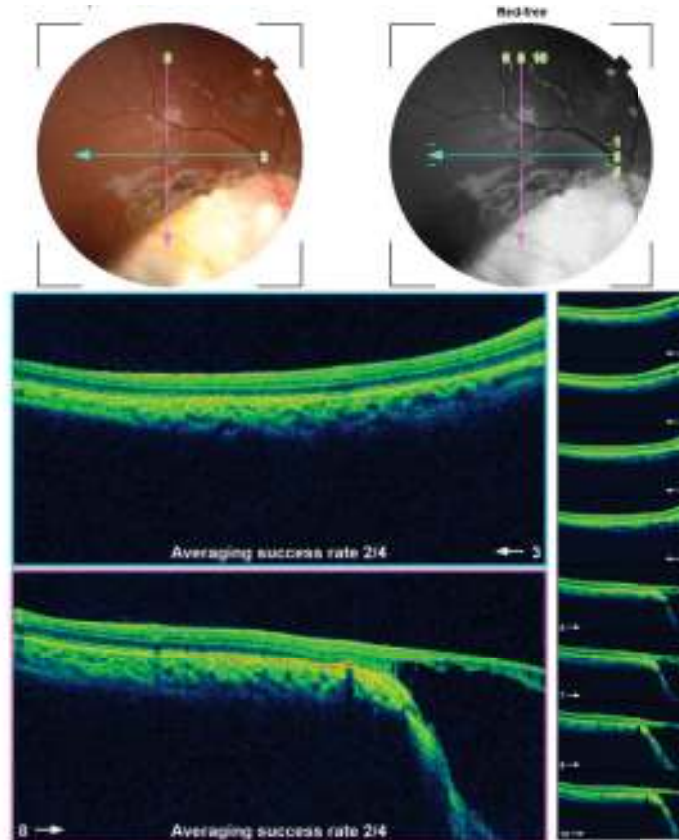


Figure 2: OCT image of right eye of a 17 years old female patient with coloboma extending upto superior border of disc and tomography showing an excavated “Y-shaped” image in coloboma.

Pradesh, India were included in this observational prospective study over a period of 15 months from October 2018 to December 2019. All methods were adhered to the tenets of the ethical standards committee on human experimentation (institutional or regional) and with the Helsinki Declaration of 1975, as revised in 2000. The purpose of this research was to study clinico-etiological features of patients with coloboma.

The inclusion criteria comprised of (a) ≤ 25 years of age; (b) colobomatous malformation in either eye without associated systemic features. Children with non-syndromic ocular anomalies were selected in order to exclude dysmorphic children who were likely to have chromosomal abnormalities or phenocopies due to a teratogen; (c) patients and/or guardians giving proper consent to comply with study requirements. The exclusion criteria comprised of (a) Subjects with clearly identifiable systemic syndrome were excluded; (b) patients having developmental eye abnormalities described as “coloboma” by the referring physician, but who had defects not related to optic fissure closure; and (c) cases with history of laser photocoagulation or any ocular surgical

intervention.

Every case was examined by the same ophthalmologist. The anterior segment was examined with slit lamp. Dilated fundal examination was performed by direct and indirect ophthalmoscopy. Each case was examined for systemic abnormalities by the ophthalmologist and a paediatrician/ physician. Demographic and clinical data included age at presentation, gender and parental consanguinity. For infants and developmentally delayed children who could not participate in formal visual acuity assessment, the ability of the patient to fix and follow, the presence of any ocular fixation preference, and/or binocular Teller visual acuity was noted. The best-corrected visual acuity was measured with a Snellen chart or Teller chart where possible. The presence of associated ocular anomalies and history of prophylactic laser photocoagulation was recorded. Standard Domain Optical Coherence Tomography (SDOCT) was done in cooperative patients.

The patient information was recorded in data collection form. Quantitative data were expressed as Mean \pm SD (Standard Deviation) and qualitative

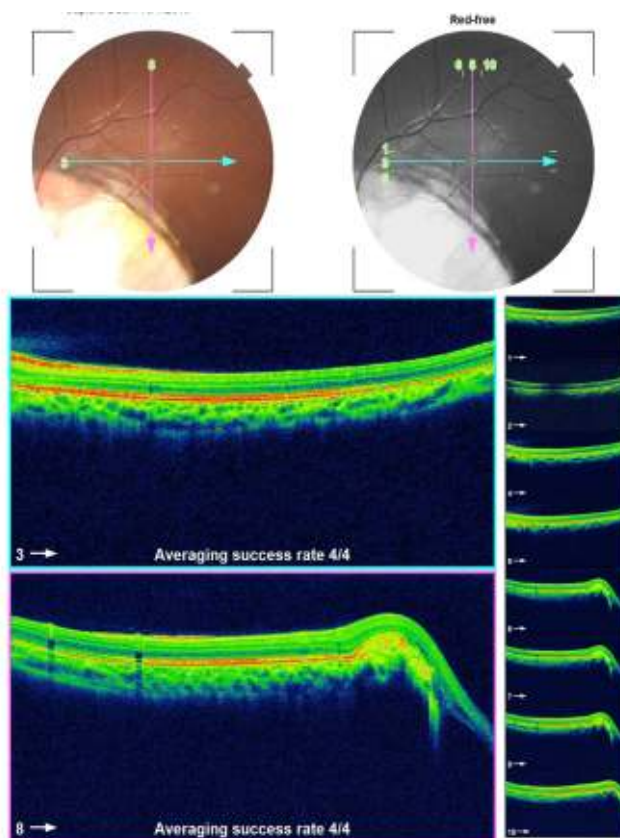


Figure 3: OCT image of left eye of a 21 years old male patient with coloboma extending upto disc and tomography showing that the margin of the coloboma having gradual transitions or sudden change into an intercalary membrane (ICM).

variables were expressed using percentages. Statistical analysis was performed using data analyses tool of Microsoft Excel 2007.

RESULTS:

One hundred and twenty four eyes of 80 patients were studied, comprising 45 (56.25%) males and 35 (43.75%) females. Mean age at presentation was 11.8± 2.25 years (range 1 month to 25 years) . Parental consanguinity was documented in 7 (8.75%) of the patients (Table 1). There were 44 (55%) patients with bilateral colobomata and 36 (45%) with unilateral involvement. Among 80 patients, 25 (31.25%) cases had only anterior colobomas, 31(38.75%) cases had only posterior involvement and 24 (30%) cases had both anterior and posterior colobomas Among the 44 patients with bilateral involvement, 6 had bilateral anterior segment involvement (lens and/or iris) only, 17 had bilateral posterior segment involvement (optic disc and/or retina) only, and 21 had involvement of both the anterior and posterior segments. (Table: 2)

Table 1: Demography of patients in the study.

<i>Age (years)</i>	Mean ± SD
Range (1month -25 years)	11.8 ± 2.25
Gender (Total 80)	Male 45 (56.25%) Female 35 (43.75%)
Parental consanguinity	7 (8.75%)

Visual acuity could not be quantified in 45 patients (56.25%,n=80) because of young age or developmental delay. Among the 45 patients in whom visual acuity could be assessed, 19 patients (42.22%,n=45) had visual acuity (>20/60 in at least 1 eye), 15 patients (33.33%,n=45) were visually impaired (<20/60 but >20/200 in at least 1 eye), and 11 patients (24.44%,n=45) were legally blind (≤20/200 in the better eye). Visual acuity of the eye affected with

Table 2 : Ocular features in cases under study.

Coloboma	unilateral	bilateral	Total (n)
Total cases	36(45%)	44(55%)	80
Total eyes	36	88	124
Anterior segment coloboma	19 (23.75%)	6 (7.5%)	25(31.25%)
Posterior segment coloboma	14 (17.5%)	17(21.25%)	31(38.75%)
Both anterior segment and posterior segment	3(3.75%)	21(26.25%)	24(30%)

Table 3: visual acuity and other ocular anomalies seen in cases.

Visual acuity in at least one eye	Number of patients N=45	Percentage
$\geq 20/60$	19	42.22%
$\leq 20/60$ to $\geq 20/200$	15	33.33%
$\leq 20/200$	11	24.44%
Concurrent ocular anomalies	Anomaly	Total N=80
	Microphthalmia	32(40%)
	Strabismus	12(15%)
	Amblyopia	24(30%)
	Nystagmus	13(16.25%)
	Cataract	10(12.5%)
	Microcornea	9(11.25%)
	Retinal detachment	2(2.5%)

coloboma ranged from 20/40 to no light perception (NLP) All eyes with only anterior segment involvement had vision $\geq 20/40$. Eyes with combined retinal and optic disc involvement, as well as eyes that were microphthalmic, had a higher frequency of visual impairment. Concurrent ocular abnormalities in order of decreasing frequency in total 80 subjects were microphthalmia (32 cases,40%), amblyopia (24 cases,30%), strabismus (12 cases,15%), cataract (10 cases,12.5%), microcornea (9 cases,11.25%), and nystagmus (13 cases,16.25%) (Table 3).

Standard domain OCT could be performed with successful imaging in 28 cases out of 80. SD-OCT in 11 cases showed a “Y-shaped” retina with a fusion of retinal layers, not being able to identify any retinal layers at this level, toward the edge of the coloboma (Figure 2). The abrupt transition zone

between the normal retina into the intercalary membrane (ICM) at the level of the coloboma was seen in 9 cases with chorioretinal layers but lacking the typical layering of normal retina (Figure 3).

DISCUSSION:

A coloboma of the choroid is characterized by congenital absence of part of the retinal pigment epithelium and choroid. It appears clinically as a prominent white zone within the ocular fundus, usually in the inferonasal quadrant. The lesion consists of a rudimentary retina with a few blood vessels over the sclera, which may be ectatic. The neurosensory retina continues as the intercalary membrane (ICM) in the area of the coloboma.^[22] Uveal coloboma can exist in isolation or in association with other ocular and systemic abnormalities. In the series described by Mann, the most frequent coloboma extended to and

beyond the superior aspect of the optic nerve and likely involved the papillomacular fibres.^[11] In our study, 58 eyes (46.77%) out of 124 included eyes were classified as type 1 or 2 and had vision less than 20/200. Other factors accounting for the reduced vision were lens opacities and associated ocular anomalies, which coexisted in 92 eyes (74.1%). Our study results (Table 2) were in resonance with a retrospective review of Nakamura and associates showing that 36% of patients had only anterior colobomas, 39% had only posterior involvement, and 29% had both anterior and posterior colobomas.^[9] Consistent with previous reports, patients with coloboma affecting the retina and optic nerve and those with microphthalmia have a more guarded visual prognosis.^[24] Compared to Nakamura's study, we found a lower prevalence of strabismus (15% vs 30%) among our patients. Shah also reported that 44% of their subjects were bilaterally visually impaired (defined as BCVA "outside normal limits") or severely visually impaired (defined as BCVA <3/60). Out of 45 patients whose visual acuity could be assessed we found that 33.33% of our patients were visually impaired (<20/60 but >20/200 in at least 1 eye) and 24.44% were legally blind (<20/200 in the better eye) 28.88% of our patients were bilaterally visually impaired or severely visually impaired. Differences in findings among studies may be explained by ascertainment methodology, examination techniques or demographics. A higher proportion of familial cases in India than elsewhere may be related to the prevailing high levels of consanguinity in the population increasing the frequency of recessive disease and modifying the genetic background. However, even in India the majority of cases are sporadic. Possible causes for sporadic cases include unrecognized recessive disease, new mutations, phenocopies (environmental factors), extramarital conceptions, chromosomal aberrations, or complex genetic mechanisms such as polygenic inheritance or gene-environment interactions.^[25] Our study found 7 cases out of 80 patients with parental consanguinity. This could be attributed to lower consanguinity in north India comparing to south India. Optic coherence tomography (OCT) of the optic nerve can help elucidate the different optic nerve anomalies that look

similar on funduscopy alone. OCT of optic nerve coloboma shows retinochoroidal-scleral excavation of the nerve. And OCT of chorioretinal coloboma may depict that neural retina continues as ICM in the area of the coloboma.^[22] This transition may be abrupt or, more often, gradual.^[26] The outer layers of the retina disappear while inner layers turn into the ICM. Our cases also showed these changes (Figure: 1& 2).

CONCLUSION:

This study delineates the etiological and clinical profile of coloboma emphasizing on proper ophthalmic diagnosis, role of OCT in fundal imaging and visual assessment of patients with coloboma. Such children may be assisted with low vision devices and rehabilitation measures. Childhood blindness has implications for infants' development, education, and future social, marital, and economic prospects. Early onset visual loss can have profound consequences on a child's motor, social, emotional, and psychological development. Coloboma can be isolated, associated with other ocular anomaly and/or associated with systemic manifestation. The visual prognosis in such eyes is linked to severity of ocular malformation and also takes into account the CNS and systemic abnormalities commonly seen with ocular coloboma. Timely diagnosis of coloboma, needful information to the parents regarding the anomaly and visual rehabilitation of such subjects should be a priority. Genetic counselling may also provide a pivotal role.

LIMITATIONS OF THE STUDY:

The limitations of our study are limited number of studied eyes, no follow up study included, difficulties to obtain the images of the entire colobomatous cavities and from the deepest area of the colobomas.

REFERENCES:

1. Coloboma, Mosby's Medical, Nursing & Allied Health Dictionary, Fourth Edition, Mosby Year-Book, 1994, p. 361.
2. Duke-Elder S. Congenital deformities of the eye. In: System of ophthalmology. London: Henry Kimpton, 1964:415–29.
3. Hornby, SJ, Adolph S, Gilbert CE, Dandona L, Foster A. Visual acuity in children with coloboma: clinical features and a new phenotypic classification system. *Ophthalmology*. 2000;107 (3): 511–20.
4. Mann I. Developmental abnormalities of the eye. Philadelphia: Lippincott, 1957:81–103.

5. Onwochei BC, Simon JW, Bateman JB, Couture KC, Mir E. Ocular colobomata. *Surv Ophthalmol.* 2000;45(3):175–94.
6. Bernstein CS, Anderson MT, Gohel C, Slater K, Gross JM, Agarwala S. The cellular bases of choroid fissure formation and closure. *Dev Biol.* 2018;15;440(2):137-151. doi: 10.1016/j.ydbio. 2018.05.010. Epub 2018 May 24.
7. Gregory-Evans K. Developmental disorders of the globe. In: Moore A, Lightman S, Eds.: *Fundamentals of clinical ophthalmology: paediatric ophthalmology.* London: BMJ Books, 2000:53–61.
8. Warburg M. Classification of microphthalmos and coloboma. *J Med Genet* 1993;30:664–9.
9. Nakamura KM, Diehl NN, Mohny BG. Incidence, ocular findings, and systemic associations of ocular coloboma: a population-based study. *Arch Ophthalmol.* 2011;129(1):69-74. doi: 10.1001/ archophthalmol. 2010.320.
10. Jeng-Miller KW, Cestari DM, Gaier ED. Congenital anomalies of the optic disc: insights from optical coherence tomography imaging. *Curr Opin Ophthalmol.* 2017;28(6):579-586.
11. Mann I . *Developmental Abnormalities of the Eye.* Cambridge University Press: London, UK, 1937. pp 65–103.
12. Yanoff M, Fine BS. *Ocular pathology: a text and atlas.* Philadelphia: Harper and Row. 1982:402–4.
13. Vieira H, Gregory-Evans K, Lim N, Brookes JL, Brueton LA, Gregory-Evans CY. First genomic localisation of oculo-oto-dental syndrome with linkage to chromosome 20q13.1. *Invest Ophthalmol Vis Sci.* 2002;43:2540–5.
14. Gopal L, Badrinath SS, Kumar KS, Doshi G, Biswas N. Optic disc in fundus coloboma. *Ophthalmology.* 1996; 103:2120–6.
15. Pons JC, Imbert MC, Elefant E, Roux, C, Herschkorn, P, Papiernik, E. Development after exposure to mifepristone in early pregnancy. *Lancet* 1991;338:763.
16. Pallotta R, Fusilli P, Sabatino G. Confirmation of the colobomatous macrophthalmia with microcornea syndrome: report of another family. *Am J Med Genet.* 1998;76:252–4.
17. Zlotogora J, Legum C, Raz J, et al. Autosomal recessive colobomatous microphthalmia. *Am J Med Genet.* 1994;49:261–2.
18. Porges Y, Gershoni BR, Leibur R, et al. Hereditary microphthalmia with colobomatous cyst. *Am J Ophthalmol.* 1992;114:30–4.
19. Barros NP, Medina C, Mendoza R, et al. Unexpected familial recurrence of iris coloboma. A delayed mutation mechanism? *Clin Genet.* 1995;48:160–1.
20. Miller MT, Stromland K. Teratogen update—thalidomide: a review, with a focus on ocular findings and new potential uses. *Teratology.* 1999; 60:306–21.
21. Abdelrahman A and Conn R. Eye abnormalities in fetal alcohol syndrome. *Ulster Med J.* 2009;78:164–5.
22. Gopal L, Khan B, Jain S, Prakash VS. A Clinical and Optical Coherence Tomography Study of the Margins of Choroidal Colobomas. *Ophthalmology.* 2007;114:571–580.
23. Schubert HD. Structural Organization of Choroidal Colobomas of Young and Adult Patients and Mechanism of Retinal Detachment. *Trans Am Ophthalmol Soc.* 2005;103:457–472.
24. Hornby SJ, Adolph S, Gilbert CE, Dandona L, Foster A. Visual acuity in children with coloboma: clinical features and a new phenotypic classification system. *Ophthalmology.* 2000;107(3):511–520.
25. Hornby SJ, Ward SJ, Gilbert CE, et al. Environmental risk factors in the aetiology of congenital malformations of the eye in children in South India. *Arch Trop Paediatr.* 2002;22:67–77.
26. Gopal L. A clinical and optical coherence tomography study of choroidal colobomas. *Curr Opin Ophthalmol.* 2008;19:248–54.

Cite this article as: Sirohi N, Kumar J, Vats P: A Clinical and Optical Coherence Tomography Study of Coloboma in a Tertiary Health Care Centre of Uttar Pradesh. . *PJSR* ;2020:13(1):35-41.
 Source of Support : Nil, Conflict of Interest: None declared.